

## **EFFECT OF SHARK LIVER OIL ON HYPERCHOLESTEROLEMIA INDUCED RENAL CORTICAL DAMAGE IN MALE ALBINO RAT.**

**Seleim, Magda A. A.\* and Amel M. M. Abdel-Hafez\*\***

**\* Food Science and Technology Dept., Faculty of Agric., Assiut Univ.**

**\*\* Department of Histology, Faculty of Medicine, Assiut University**

### **ABSTRACT**

The present study was designed to investigate the impact of high cholesterol diet on serum lipid profile and renal cortical structure in male albino rats. In addition, the possible effect of shark liver oil in reducing hypercholesterolemia induced renal cortical structural changes was studied in correlation with serum lipid profile.

Results indicated that the highest decrease in rat serum triglycerides, total cholesterol, LDL-cholesterol and VLDL-cholesterol were in group feeding on 2% shark liver oil for 30 days of treatment (28.2%, 23.6%, 20.3% and 28.2%, respectively). On the other hand, the data showed that the highest increase in rat serum HDL-cholesterol was in 2% shark oil feeding group (22.5%).

Hypercholesterolemia induced prominent podocyte injury characterized by densely stained nuclei, vacuolated cytoplasm. Some renal corpuscles exhibited tuft attachment to Bowman's capsule. Tubular injury was also observed involving intracellular vacuoles and intensely stained nuclei. Also, partial loss of apical brush membrane and basal striation has been noticed in tubular epithelial cells. Shark liver oil dietary supplement noticeably corrected the changes in serum lipid profile and reduced hypercholesterolemia associated renal cortical damage to become comparable with that of the control.

Also, shark liver oil could be considered as an excellent source of omega-3 fatty acids, squalene and other natural antioxidants which could be used as a good treatment for reducing hypercholesterolemia in serum lipids.

These observations highlight the beneficial effect of shark liver oil, as a health supplement, in ameliorating the renal injury associated with hypercholesterolemia. These effects might be attributed to the antioxidant and hypolipidemic effects of shark liver oil.

**Keywords:** Shark oil, Hypercholesterolemia, Renal Cortical and Triglycerides

### **INTRODUCTION**

The fish oils, constitute an important source of omega-3 polyunsaturated fatty acids (PUFA). The omega-3 (PUFA) provides several benefits to the human health; they are essential for the development and function of certain organs and for several biochemical and physiological responses of the organism (Meyer *et al.*, 1999).

The consumption of omega-3 (PUFA) prevents the appearance of cardiovascular diseases, due to the hypolipidemic (Harper and Jacobson, 2001) and antithrombotic (Knapp, 1997) property of these fatty acids.

Hypercholesterolemia, recognized as contributing to atherosclerosis, is also considered as an independent risk factor for renal injury (Oda & Keane, 1999). Numerous studies have shown that elevated plasma cholesterol can exacerbate renal disease (Vazquez-Perez, *et al.*, 2001).

Several previous studies have concerned with the effect of hypercholesterolemia on renal tissue for long periods with the end result of focal glomerulosclerosis and proteinuria that progress rapidly to renal failure (Deepa & Varalakshmi, 2006). However, there is little information about the early effect of hypercholesterolemia on renal injury (Joles, *et al.*, 2000).

Shark liver oil, as a health supplement, has been suggested to be used in the treatment of infectious diseases (Szostak & Szostak-Wegierek, 2006) and in cancer therapy (Hajimoradi, *et al.*, 2009). Shark liver oil is considered the richest source of squalene which has been reported to be hypolipidemic (Kelly, 1999) and anticarcinogenic (Reddy & Couvreur, 2009), in addition to its antioxidant and membrane stabilizing properties (Ko, *et al.*, 2002). No available information has been obtained regarding the effect of shark liver oil on hypercholesterolemia-induced renal damage.

Therefore, the aim of the present work was to investigate the effect of a short term high cholesterol diet (for 10 days) on serum lipid profile and structure of the renal cortex of adult male albino rats and to evaluate the possible preventive effect of dietary supplement with shark liver oil in two different concentrations against the hypercholesterolemia-induced deleterious effects.

## **MATERIALS AND METHODS**

### **Materials**

1-Shark liver oil was obtained from Aden Gulf, Yemen.

2-Basal diet: Normal diet provided from animal house of Faculty of Medicine, Assiut University.

3-Rich Cholesterol diet contain basal diet + 1 g Brain (gavage)

### **Animals:**

Adult male albino rats weighing 200-250 gm, were obtained from the experimental animal house of Faculty of Medicine, Assiut University, Assiut, Egypt.

### **Methods:**

#### **Biological evaluation:**

##### **1- Experimental design:**

Forty male albino rats were isolated in clean properly ventilated cages under normal conditions with an appropriate temperature with free access of water. Rats were divided into two groups according to the following scheme:

G1: Rats fed on basal diet (negative control) for forty days (n= 10).

G2: Rats fed on a hypercholesterolemia diet for ten days (n= 30).

Then, the second group was subdivided into three subgroups (n= 10).

G2a: Rats fed on a hypercholesterolemia diet, then fed on basal diet to the end of experiment. (positive control).

G2b: Rats fed on a hypercholesterolemia diet, then fed on basal diet + 10% shark liver oil to the end of experiment.

G2c: Rats fed on a hypercholesterolemia diet, then fed on basal diet + 20% shark liver oil to the end of experiment.

At the end of the experiment, blood samples were collected from the animals of different groups studied. Then, animals were sacrificed and tissue specimens were taken from the right kidney and processed for histological examination of the renal cortex.

#### **2- Biochemical Examination**

Total cholesterol concentration was measured according to Allain *et al.* (1974) using commercially available kits (cholesterol C-test, ELITECH diagnostics, French).

HDL cholesterol concentration was measured according to Lopes-Virella *et al.* (1977) using commercially available kits (HDL-cholesterol test, ELITECH diagnostics, French).

Triglyceride concentrations were measured colorimetrically at wavelength 546 nm with commercially available kits (Triglycerides-test, ELITECH diagnostics, French), according to Bucolo and David (1973).

The concentration of LDL cholesterol was calculated as the equation of Friedewald *et al.* (1972) as follows:

$$\text{LDL-cholesterol} = [\text{Total chol.} - \text{HDL-cholesterol} - \text{TG}/5].$$

The quotient TG/5 are used as a measure of VLDL-cholesterol concentration. The TG: VLDL-cholesterol ratio is constant at about 5:1 (Friedewald *et al.*, 1972).

#### **3- Histological Examination:**

1- Tissue specimens were fixed in 10% neutral formalin and processed for Harris Haematoxylin and Eosin (H&E) stain for general histological examination according to Drury and Wallington (1980).

2- Tissue specimens were fixed in 4% gluteraldehyde, post fixed in osmium tetroxide, processed and embedded in epon. Semithin sections (0.5  $\mu\text{m}$  or 1  $\mu\text{m}$ ) were stained with toluidine blue (Gupta, 1983) and examined by light microscope.

## **RESULTS AND DISCUSSION**

The data presented in Tables (1-2) show the effect of adding shark liver oil in different levels to rat diets on serum lipids.

Table (1) showed that the highest decrease in rat serum triglycerides was in group feeding on 2% shark oil for 30 days of treatment (20.38%). Such finding are in agreement with Ruiz-Gutierrez *et al.* (1999) who reported that the decrement in rat serum triglycerides may have been due to inhibition of hepatic triacylglycerol synthesis, and stimulation of hepatic peroxisomal  $\beta$ -oxidation.

Data presented in Table (2) showed that the highest decrease in rat serum total cholesterol was in group 3c which treated with 2% shark oil (21.82%); whereas lowest decrease was in group 1b feeding on 1% shark oil.

Such trend are in agreement with Hirose *et al.* (1991) who found that sesamin lowered both serum and liver cholesterol levels by inhibiting absorption and synthesis of cholesterol simultaneously. Whereas there is a decrease in lymphatic absorption of cholesterol accompanying an increase in fecal excretion of neutral, but not acidic, steroids, particularly when the cholesterol-enriched diet is given.



**Table (3): Effect of adding shark liver oil on rat serum HDL-cholesterol.**

Treatments*	After depletion period	After hypercholesterolemic period	During repletion period	Increase %
G 1	30,20	--	37,41	--
G 2a	30,20	27,90	30,86	10,61
G 2b	30,20	27,90	41,70	30,13
G 2c	30,20	27,90	48,12	50,93

**Table (4): Effect of adding shark liver oil on rat serum LDL-cholesterol.**

Treatments*	After depletion period	After hypercholesterolemic period	During repletion period	Reduction %
G 1	09,17	--	07,79	--
G 2a	09,17	93,12	88,02	0,48
G 2b	09,17	93,12	02,44	40,42
G 2c	09,17	93,12	46,24	47,47

**Table (5): Effect of adding shark liver oil on rat serum VLDL-cholesterol.**

Treatments*	After depletion period	After hypercholesterolemic period	During repletion period	Reduction %
G 1	26,43	--	26,80	--
G 2a	26,43	41,28	39,72	3,78
G 2b	26,43	41,28	32,06	18,03
G 2c	26,43	41,28	29,64	20,38

\* G1: negative control

G2b: Fed on 10% shark liver oil.

G2a: Positive control

G2c: Fed on 20% shark liver oil.

**General histological examination:**

In control animals (Group I), the renal cortex is characterized by the presence of renal corpuscles, proximal convoluted tubules (PCT) and distal convoluted tubules (DCT). Each renal corpuscle consists of a glomerular capillary tuft surrounded by capsular space and Bowman's capsule. The PCT is lined by a high cuboidal epithelium with deeply stained acidophilic cytoplasm and rounded nuclei. The DCT is lined by low cuboidal cells with pale acidophilic cytoplasm and rounded nuclei. The DCT exhibits a wider lumen than that of PCT (Fig. 1). In semithin sections; the glomerular capillaries are defined by the prominent glomerular basement membrane. Podocytes invest the capillary loops and have pale nuclei and extensive branching pale stained cytoplasm. The parietal layer of Bowman's capsule is lined by simple squamous epithelium. The mesangial cells are identifiable by their densely stained nuclei and surrounding deeply stained mesangium (Fig. 2). The cells lining the PCT have apical brush border and well defined basal striations. Their nuclei are central and pale with prominent nucleoli. The cells of DCT have no apical brush border and their nuclei appear apical in position (Fig. 3).

The renal cortices of non treated high cholesterol diet-fed animals (Group IIa) exhibit structural changes mainly involving the renal corpuscles with some affection of PCT & DCT. Many renal corpuscles show attachment of the glomerular tufts to Bowman's capsule with a noticeable reduction of the urinary space. Both PCT & DCT show numerous intracellular vacuoles. Some exfoliated cells are observed in the lumen of some renal tubules (Fig. ٤). In semithin sections, many podocytes have intensely stained nuclei and vacuolated cytoplasm. Mesangial cells and their matrix appear relatively unchanged (Fig. ٥). Some nuclei of the tubular epithelial cells appear intensely stained. Many PCTs show partial loss of their apical brush membranes and basal striations (Fig. ٦).

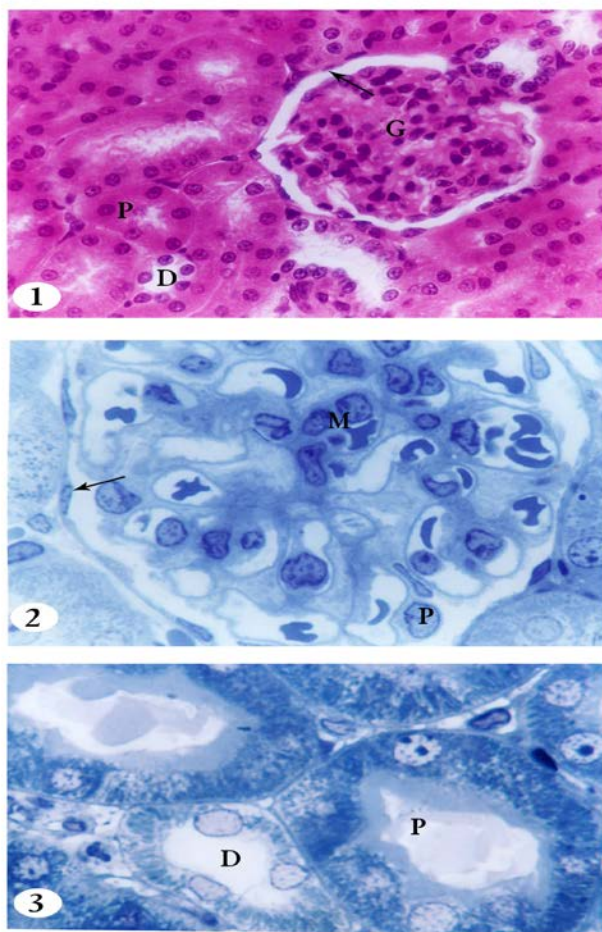
In the renal cortex of ١٠% shark oil treated high cholesterol diet-fed animals (Group IIb), most renal corpuscles show absence of adhesions between the glomerular capillary tufts and Bowman's capsule. Less vacuoles are observed in the cytoplasm of tubular epithelial cells with fewer exfoliated cells in the lumen of PCT & DCT in comparison with those of the renal cortex of group IIa animals (Fig. ٧). In semithin sections, most podocytes exhibit pale stained nuclei with no vacuoles in their cytoplasm (Fig. ٨). The renal tubules show better structural preservation compared with those of group IIa animals. Most of their tubular cells have pale stained nuclei. The integrity of apical brush border is more preserved in many PCTs (Fig. ٩).

In the renal cortex of ٢٠% shark oil treated high cholesterol diet-fed animals (Group IIc), most renal corpuscles and tubules appear relatively normal with a more or less similar structure to that of control animals (Fig. ١٠). Examination of the renal cortex of group IIc animals show a relatively normal appearance of the podocytes of most renal corpuscles (Fig. ١١). Few tubular epithelial cells show vacuoles in their cytoplasm. The integrity of apical brush borders and basal striations are more preserved in most PCTs (Fig. ١٢).

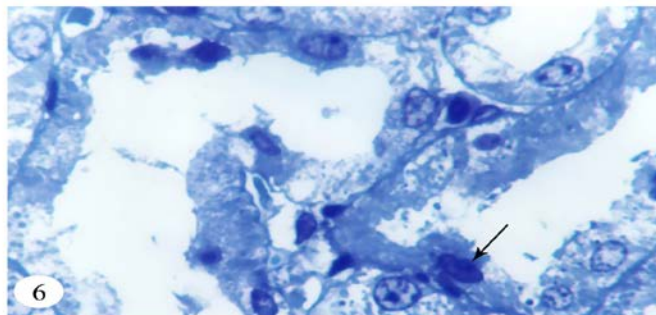
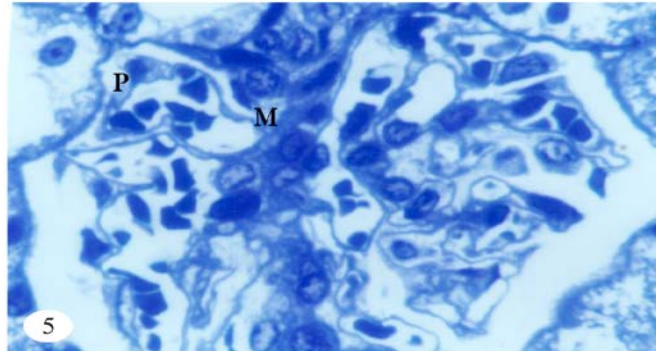
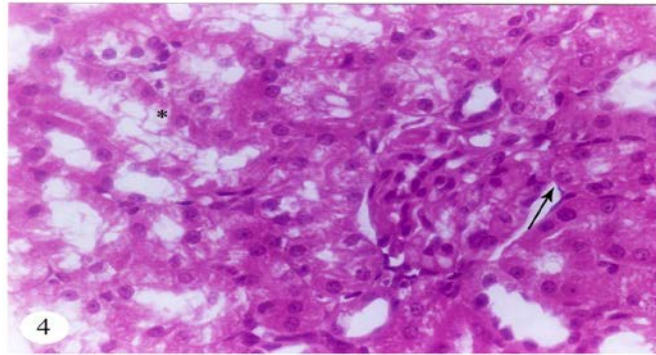
The results of the present work demonstrated the deleterious effects of short-term high cholesterol diet feeding (for ١٠ days) on rat serum lipid profile and renal cortical structure.

The structural renal damage primarily involved the renal corpuscles which revealed densely stained nuclei and vacuolated cytoplasm of many podocytes. The podocyte injury observed in the present work was in accordance with the work of Attia, *et al.* (٢٠٠٤), who studied the effect of hypercholesterolemia inducing diet in rats. However, in hyperlipidemic Apo E null mice (an experimental model for spontaneous hyperlipidemia) podocytes showed normal electron microscopic structure (Bruneval, *et al.*, ٢٠٠٢). This controversy may be due to different rodent models used in these studies. Podocyte injury would progress to detachment of podocyte from the glomerular basement membrane (Kriz, *et al.*, ١٩٩٨) and thus could explain the attachment of glomerular tufts to the Bowman's capsule (Shirato, *et al.*, ١٩٩٦).

Similarly, glomerular tuft adhesion to the Bowman's capsule was observed in rabbits fed hypercholesterolemia inducing diet for ١٢ weeks (Vazquez-Perez, *et al.*, ٢٠٠١).

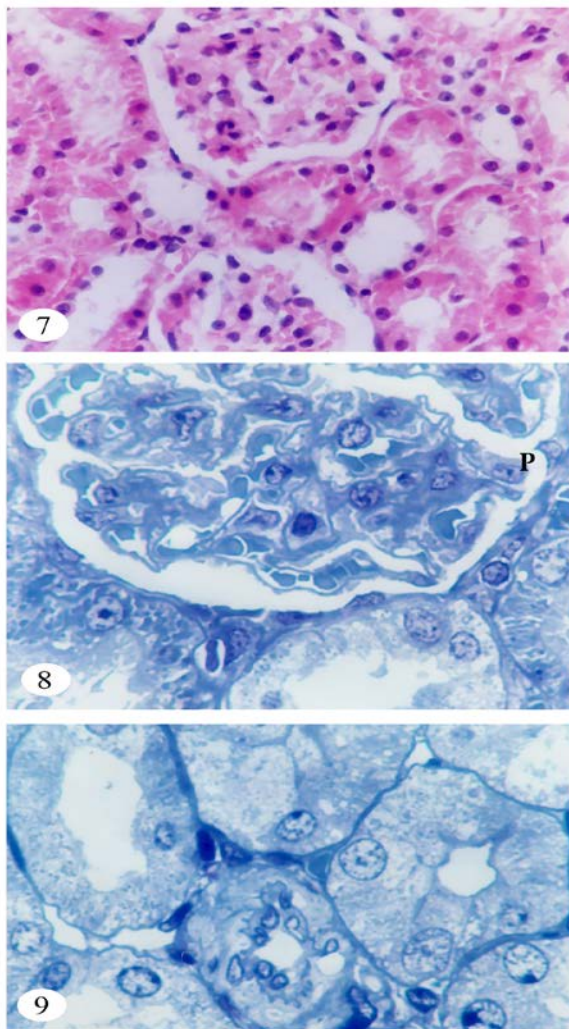


- Fig. 1:** A photomicrograph of the renal cortex of a control rat. The renal corpuscle shows the glomerulus (G) with its capillary tufts surrounded by capsular space and Bowman's capsule (arrow). The epithelium of PCT is lined by high cuboidal cells with intensely stained acidophilic and rounded nuclei (P). The DCT is lined by low cuboidal cells with pale stained cytoplasm and rounded nuclei (D). (H&E x400)
- Fig. 2:** A photomicrograph of the renal cortex of a control rat showing a part of a renal corpuscle. Glomerular capillaries are defined by the prominent glomerular basement membrane. Podocytes (P) have extensive branching pale stained cytoplasm & pale stained nuclei. Note the mesangial cells (M) and the squamous cells of Bowman's capsule (arrow) (Toluidine blue x1000)
- Fig. 3:** Another photomicrograph of the renal cortex of a control rat. The cells of PCT (P) have apical brush border & well formed basal striations. Their nuclei are central and pale with prominent nucleoli. The DCT (D) exhibits a wider lumen with pale apical nuclei and no brush border in their lining cells. (Toluidine blue x1000)

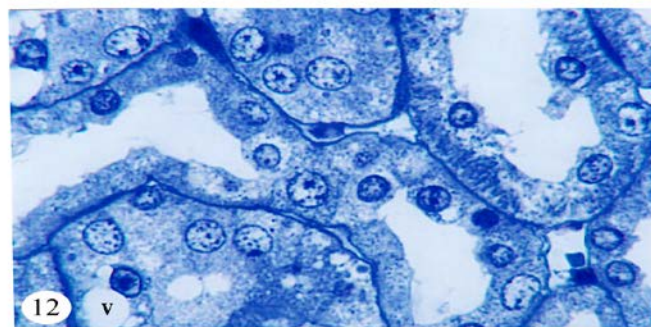
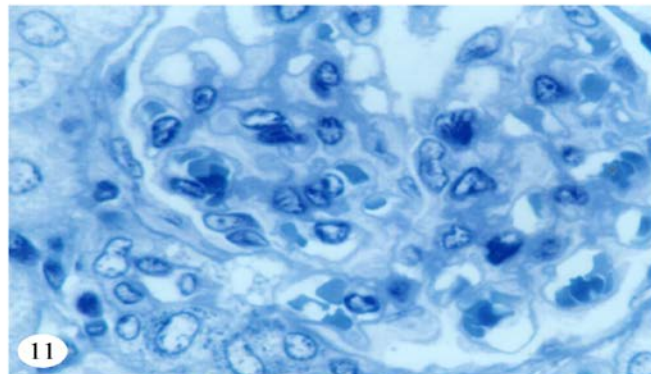
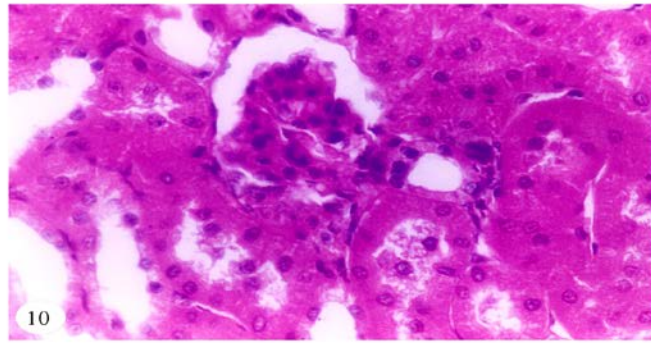


- Fig. 4: A photomicrograph of the renal cortex of a non treated high cholesterol diet-fed rat. Notice the attachment of glomerular capillary tufts to Bowman's capsule (arrow) with a noticeable reduction of the capsular space. Numerous intracellular vacuoles can be noticed in many of the tubular cells involving both PCT & DCT (asterisk). (H&E x400)
- Fig. 5: A photomicrograph of the renal cortex of a non treated high cholesterol diet-fed rat. Many podocytes have intensely stained nuclei and vacuolated cytoplasm (P). Mesangial cells (M) and their matrix appear relatively unchanged. (Toluidine blue x1000)
- Fig. 6: Another photomicrograph of the renal cortex of a non treated high cholesterol diet-fed rat. Some tubular cells have intensely stained nuclei (arrow). Notice the partial loss of apical brush border and basal striation of PCTs. (Toluidine blue x1000)





- Fig. 7:** A photomicrograph of the renal cortex of a 10% shark oil treated high cholesterol diet-fed rat. No adhesion can be observed between the glomerular capillary tufts and Bowman's capsule. Less vacuoles are noticed in the tubular cells of PCT & DCT compared to those of non treated high cholesterol diet-fed rats. Few exfoliated cells are seen in the lumen of some renal tubules. (H&E  $\times 400$ )
- Fig. 8:** A photomicrograph of the renal cortex of a 10% shark oil treated high cholesterol diet-fed rat. Podocytes (P) exhibit pale stained nuclei with no vacuoles in their cytoplasm. (Toluidine blue  $\times 1000$ )
- Fig. 9:** Another photomicrograph of the renal cortex of a 10% shark oil treated high cholesterol diet-fed rat showing pale stained nuclei of tubular epithelial cells. Notice the more preservation of the apical brush border of PCTs. (Toluidine blue  $\times 1000$ )



- Fig. 10: A photomicrograph of the renal cortex of a 2% shark oil treated high cholesterol diet-fed rat. The renal corpuscle and tubules appear relatively normal. (H&E x400)
- Fig. 11: A photomicrograph of the renal cortex of a 2% shark oil treated high cholesterol diet-fed rat showing the relatively normal appearance of glomerular podocytes. (Toluidine blue x1000)
- Fig. 12: Another photomicrograph of the renal cortex of a 2% shark oil treated high cholesterol diet-fed rat showing vacuoles (v) in the cytoplasm of few tubular epithelial cells with more preservation of the apical brush border and basal striations of most proximal tubular cells. (Toluidine blue x1000)

Regarding the renal tubules, variable degrees of damage have been observed in the renal cortex of HCD fed rats. These include intracellular vacuoles, intensely stained nuclei, partial loss of apical brush membrane in proximal convoluted tubules (PCT) and loss of basal striation in both PCT and distal convoluted tubules (DCT). This was in agreement with Bobulescu, *et al.* (2008) who studied the effect of renal lipid accumulation on rat proximal tubular cells. It has been reported that renal tubular damage may occur primarily by lipemic oxidative injury and cellular dysfunction (Sudhahar, *et al.*, 2008). Also, renal tubular damage has also been suggested to be secondary to hypercholesterolemia-induced glomerular damage and proteinuria leading to tubular luminal obstruction by protein casts (Rasch, *et al.*, 2002).

Shark liver oil has been administered orally in this work to HCD fed rats in two different concentrations (10% & 20%) for one month. It revealed a noticeable reduction of hypercholesterolemia-induced renal structural changes in most renal corpuscles and tubules with the restoration of serum lipid profile to normal values. The use of the low concentration (10% shark liver oil) showed substantially low renal damage, whereas nearly normal renal architecture was observed following the use of the high concentration (20% shark liver oil). These results indicate a cytoprotective effect of shark liver oil against hypercholesterolemia-induced renal damage which is most probably mediated through its antioxidant properties and hypolipidemic effect. This effect of shark liver oil may be attributed to its great content of squalene (Vazquez-Perez, *et al.*, 2001). Squalene is suggested to have cholesterol lowering effect and an antioxidant effect (Farvin, *et al.*, 2003).

**In conclusion**, shark liver oil administration effectively restored most of high cholesterol diet-induced deleterious effects suggesting that this medicinal supplement can play a therapeutic role against both disturbed serum lipid profile and renal cortical damage associated with dietary hypercholesterolemia. The effect was better with 20% than 10% shark liver oil administration. The possible prophylactic effect of shark liver oil supplement with high cholesterol diet feeding for longer duration remains to be elucidated.

## REFERENCES

- Allain, C.C.; Poon, L.S.; Chan, C.S.G.; Richmond, W. and Fu, P.C. (1974). Enzymatic determination of total serum cholesterol. *Clin. Chem.* 20, 470-472.
- Attia DM, Feron O, Goldschmeding R, Radermakers LH, Vaziri ND, Boer P, Balligand J-L, Koomans HA and Joles JA (2003): Hypercholesterolemia in rats induces podocyte stress and decreases renal cortical nitric oxide synthesis via an angiotensin II type 1 receptor-sensitive mechanism. *J Am. Soc. Nephrol*, 10:949-957.
- Bobulescu IA, Dubree M, Zhang J, McLeroy P and Moe OW (2008): Effect of renal lipid accumulation on proximal tubule Na/H exchange and ammonium secretion. *Am J Physiol Renal Physiol*, 294: F1310-F1322.
- Bruneval P, Bariety J, Belair M-F, Mandet C, Heudes D and Nicoletti A (2002): Mesangial expansion associated with glomerular endothelial cell activation and macrophage recruitment is developing in hyperlipidemic apoE null mice. *Nephrol Dial Transplant*, 17: 2099-2107.

- Bucolo, G. and David, H. (1973). Quantitative determination of serum triglycerides by the use of enzymes. *Clin. Chem.* 19, 476-482.
- Deepa PR and Varalakshmi P (2006): Favourable modulation of the inflammatory changes in hypercholesterolemic atherogenesis by a low-molecular-weight heparin derivative. *Int J Cardiol*, 106: 338-347.
- Drury RAB and Wallington EA (1980): *Careton's Histology Technique*, 6<sup>th</sup> Edition. Oxford University Press, Oxford. New York. Toronto, 129-130.
- Farvin KHS, Anandan R, Kumar SHS, Shiny KS, Sanakar TV and Thankappan TK (2004): Effect of squalene on tissue defense system in isoproterenol-induced myocardial infarction in rats. *Pharmacol Res*, 50: 231-236.
- Friedewald, W.T.; Levy, R.I. and Fredrickson, D.S. (1972). Estimation of the concentration of low-density Lipoprotein cholesterol in plasma without use of the preparative ultracentrifuge. *Clin. Chem.* 18, 499-502.
- Gupta PD (1983): Ultrastructural study on semithin section. *Science Tools*, 30: 6-7.
- Hajimoradi, M.; Hassan, Z.M.; Pourfathollah, A.A.; Daneshmandi, S. and Pakravan, N. (2009). The effect of shark liver oil on the tumor infiltrating lymphocytes and cytokine pattern in mice. *J. Ethnopharmacol*, 126: 560-570.
- Harper, C.R. and Jacobson, T.A. (2001). The fats of life: The role of omega-3 fatty acids in the prevention of coronary heart disease. *Archives of International Medicine*, 161, 2180-2192.
- Hirose, N.; Inoue, T.; Nishihara, K.; Sugano, M.; Akimoto, K.; Shimizu, S. and Yamada, H. (1991). Inhibition of cholesterol absorption and synthesis in rats by sesamin. *J. Lipid Res*. 32, 629-638.
- Joles JA, Kunter U, Janssen U, Kriz W, Rabelink, TJ, Koomans HA and Floege J (2000): Early mechanisms of renal injury in hypercholesterolemic or hypertriglyceridemic rats. *J Am Soc Nephrol*, 11: 669-683.
- Kelly, G.S. (1999). Squalene and its potential clinical uses. *Altern Med Rev.*, 4: 29-36.
- Knapp, H.R. (1997). Dietary fatty acids in human thrombosis and hemostasis. *American J. of Clinical and Nutrition*, 65, 16870-16980.
- Ko, T.F.; Weng, T.M. and Chiou, R.Y. (2002). Squalene content and antioxidant activity of *Terminalia catappa* leaves and seeds. *J. Agric. Food Chem.*, 50: 5343-5348.
- Kriz W, Gretz N and Lemley KV (1998): Progression of glomerular diseases: Is the podocyte the culprit? *Kidney Int*, 54: 687-697.
- Kushiro, M.; Masaoka, T.; Hageshita, S.; Takahashi, Y.; Ide, T. and Sugano, M. (2002). Comparative effect of sesamin and episesamin on the activity and gene expression of enzymes in fatty acid oxidation and synthesis in rat liver. *J. Nutr. Biochem*. 13, 289-290.
- Lopes-Virella, M.F.; Stone, P.; Ellis, S. and Coiweil, J.A. (1977). Cholesterol determination in High-Density Lipoproteins separated by three different methods. *Clin. Chem.* 23, 882-884.
- Meyer, B.J., Tsvivis, E., Howe, P.R.C.L. and Calvert, G.D. (1999). Polyunsaturated fatty acid content of food: differentiating between long and short chain omega-3 fatty acids. *Food Australia*, 51, 81.
- Oda H and Keane WF (1999): Recent advances in statins and the kidney. *Kidney Int*, 51(Suppl 62): S2-S6.

- Rasch R, Nyengaard JR, Marcussen N and Meyer TW (2002): Renal structural abnormalities following recovery from acute puromycin nephrosis. *Kidney Int*, 62: 496-506.
- Reddy, L.H. and Couvreur, P. (2009). Squalene: a natural triterpene for use in disease management and therapy. *Adv. Drug Deliver Rev.*, 61: 1412-1426.
- Ruiz-Gutierrez, V.; Perez-Espinosa, A.; Vazquez, C.M. and Santa-Maria, C. (1999). Effects of dietary fats on lipid composition and antioxidant enzymes in rat liver. *British J. Nutr.* 82, 233-241.
- Shirato I, Hosser H, Schulze M, Susani M, Kerjaschki D and Mooney A (1996): The development of focal segmental glomerulosclerosis in Masugi nephritis is based on progressive podocyte damage. *Virchows Arch*, 429: 255-273.
- Sudhakar V, Kumar SA, Varalakshmi P and Sujatha V (2008): Protective effect of lupeol and lupeol linoleate in hypercholesterolemia associated renal damage. *Mol Cell Biochem*, 317: 11-20.
- Szostak WB and Szostak-Wegierek S (2006): Health properties of shark oil. *Przegł Lekarski*, 63: 223-226.
- Vazquez-Perez S, Aragoncillo P, de las Heras N, Navarro-Cid J, Cediell E, Sanz-Rosa D, Ruilope LM, Diaz C, Hernandez G, Lahera V and Cachofeiro V (2001): Atorvastatin prevents glomerulosclerosis and renal endothelial dysfunction in hypercholesterolemic rabbits. *Nephrol Dial Transplant*, 16(Suppl 1): 40-44.

**تأثير استخدام زيت كبد الحوت في تصحيح التغيير الحادث في قشرة الكلى الناتج عن زيادة نسبة الكوليستيرول في الدم لذكور الفئران الألبينو  
ماجدة عبد الحميد أحمد سليم\* و أمل مرزوق محمد عبد الحافظ\*\*  
\* قسم علوم وتكنولوجيا الأغذية- كلية الزراعة- جامعة أسيوط  
\*\* قسم الهستولوجى - كلية الطب- جامعة أسيوط**

أجريت هذه الدراسة لتوضيح تأثير استخدام الوجبات الغذائية ذات المستوى المرتفع من الكوليستيرول على ليبيدات الدم في ذكور الفئران الألبينو وتأثير ذلك على تركيب خلايا الكلى. بالإضافة إلى تأثير استخدام زيت كبد الحوت في خفض ليبيدات الدم المسبب للتدهور في خلايا الكلى. وقد أوضحت النتائج أن استخدام زيت كبد الحوت بتركيز 20% لفترة 30 يوم في تغذية الفئران أدى إلى انخفاض واضح في تركيز كل من الجلسريدات الثلاثية والكوليستيرول الكلى والكوليستيرول منخفض الكثافة، بينما حدث زيادة واضحة في الكوليستيرول مرتفع الكثافة. ومن جهة أخرى وجد أن الزيادة في كوليستيرول الدم أدى إلى إصابة واضحة في خلايا قشرة الكلى التي تميزت بزيادة اصطبغ الانوية وحدوث فجوات بالسيوبلازم وكذلك وجد أن بعض الجسيمات الكلوية أوضحت التصاق الخصل لمحفظه باومان. كما لوحظ إصابة الأنابيب التي اشتملت على فجوات داخل الخلايا بالإضافة إلى فقد جزئي للسطح العلوي والتخطيطات السفلية للخلايا الطلائية المبطنة للأنابيب الكلوية. بصفة عامة نجد أن استخدام زيت كبد الحوت أدى إلى تحسين مستوى ليبيدات الدم وكذلك تصحيح التغيير الحادث في تركيب قشرة الكلى لتصبح مقاربة للتركيب الطبيعي.

**قام بتحكيم البحث**

كلية الزراعة - جامعة المنصورة  
كلية الزراعة - جامعة كفر الشيخ

أ.د / أحمد عبد العزيز الرفاعى  
أ.د / محمود صابر جودة