

## POSSIBLE CAUSES AND PREVALENCE OF OCULAR CATARACT IN SOME FRESHWATER FISHES

V. H. Zaki and A. El-Shaieb\*

Department of Internal Medicine, Infectious and Fish Diseases

\*Department of Pathology, Faculty of Veterinary Medicine,

Mansoura University

### ABSTRACT

A total number of 510 freshwater fishes (*Tilapia* and *Clarias lazera* species) were collected from different places in Dakahlia and Bohira provinces and were examined for ocular opacity. The prevalence of ocular cataract among *Tilapia zilli*, *Oreochromis niloticus*, *O.-aureus* and *Clarias lazera* were 15.5%, 10.8%, 3% and 1.8% respectively. Whereas, the non infectious causes represented 66.6% and leucocytic infiltration of the eye was 25.5%, *Aspergillus flavus* was 5.88% and *Flexibacter columnaris* was 1.96%. Also histopathological examination was studied in most cases and included in the present results.

### INTRODUCTION

*Tilapia* species and catfishes have become increasingly important in fish culture, especially in warmer climates due to their good palatable taste and comparatively low prices. Special attention has been focused on different species of *Tilapia* to improve their performance (weight gain), especially under system of semi-intensive culture. Besides, endo or ectoparasitic diseases, which hinder or decrease the weight gain; there were causes of eye damages, which finally lead to severe emaciation of affected fish (Wall and Richards, 1992).

Fish with bad damage eyes are likely to have lesser body weight gain rather than normal fish due to interruption with vision process. Also, affected fish with or without free or encysted worms in eyes are rejected by consumers (Paperna, 1980 and Kabunda and Sommerville, 1984) or likely to be sold at depreciated prices.

The main objectives of this study are investigating the prevalence of eye cataract among different species of *Tilapia* as well as catfish *C.lazera* in different places and trying to identify the causative agents to solve such problem in Egyptian aquaculture.

## **MATERIAL AND METHODS**

### **Fish :**

From May 1997 till May 1999, a total number of 510 fish of different Tilapia species and *Clarias lazera* were collected alive from different fresh-water resources in Bohira and Dakahlia provinces. They were represented as *O. niloticus* (175), *O. aureus* (100), *T. zilli* (180) and *C. lazera* (55).

### **Clinical examination :**

Fish were examined directly after arrival to the laboratory by naked eye for external abnormalities, and the eyes were carefully examined. (Lucky, 1977).

### **Bacteriological and mycological examination:**

Affected eyes were dislocated from fish under complete aseptic condition. The eye content was streaked on trypticase Soy-agar and Sabaroud's Dextrose agar plates for bacteriological and mycological examination. (Lucky, 1977).

### **Parasitological examination :**

A wet-mount preparation from the eye content made on clean, dry slide to be examined directly under the microscope for parasitological examination. (Lucky, 1977).

### **Histopathological examination:**

For histopathological examination, affected eyes were fixed in 10% neutral buffer formalin and prepared by routine paraffin embedding technique according to the procedure of (Lillie and Fulmen, 1976). The paraffin sections (5-7  $\mu$ ) stained with Haematoxylin and Eosin .

## **RESULTS AND DISCUSSION**

### **Clinical examination :**

Most of the affected fishes with eye cataract showed sluggish movement, disorientation, seeking most of time at the bottom or sides of glass aquarium, motionless sometimes when kept in glass aquarium to observe their behavior compare to normal fish. Outside the water, affected fishes have weak or sometimes negative defensive reflex against external stimulation.. Some cases showed different degrees in dark discoloration of the skin in comparison to normal fish caught from the same place under the same conditions. Also, there was a great loss of body weight especially in badly affected bilateral cataract as shown in Fig 1,2. There was no obvious internal postmortum lesions observed in affected fish.

The prevalence of ocular cataract among some freshwater fishes shown in table (1).

From the presented results in table (1), it is clear that ocular cataract was more prevalent among *Tilapia zilli* with an incidence of 15.5%, followed by 10.8% in *Oreochromis niloticus*, 3% in *O. aureus* and 1.8% in *Clarias lazera*.

The high incidence of ocular cataract occurred during summer season (June and July), where collected samples were 43 out of 51 which represent 84.31% during the examination period.

#### **Bacteriological and mycological exam :**

The results of bacteriological and mycological examination from affected eyes were summarized in table (2). From the results (data) presented in table (2), it is clear that *Asprigelus flavus* (as a mycological cause of ocular cataract) isolated from 3 cases which represent 5.88%, whereas *Flexibacter columnaris* (as bacteriological cause of cataract) isolated from one case which represent 1.96%. A total number of 13 case (25.5%) showed leucocytic infiltration within the eye content, although. The non-infectious causes were 34 (66.6%).

#### **The parasitological examination :**

The affected eye contents revealed absence or negative results for the presence of larval stages of digenetic trematodes.

#### **Histopathological results :**

Microscopically, the histopathological findings were summarized in list of figures as shown in (Fig 5,6,7,8,9, and 10).

Fish eye is remarkably similar to the eye of other vertebrates, with special modification and structural adaptation suit them for function in different ecological situation exploited by fish. In addition, the eye plays an important role in judging the general health condition of fish, where it is the mirror of various infectious diseases either systemic or local. The present study revealed that affected fish with ocular cataract showed different degrees of emaciation, dark discoloration of the skin and loss of sensation against external stimuli, such observations were recorded by **Wall, and Richard (1992) and Bruno and Poppe, (1996)**.

Most collected cases with ocular cataract (Fig. 1 and 2) especially in *Tilapia zilli* obtained from Nile branch in Edfina City and Bohera Governorate, were collected in summer season with high prevalence. The present results revealed that, the causative agent of such syndrome was non-infectious. The same observations were recorded by **Bruno and Poppe (1996)**. They named their observation White Eye Syndrome which diagnosed for the first time among farmed Atlantic Salmon smolts in a few hatcheries in Norway. Affected fish appeared emaciated with characteristic crescentic-shaped white areas in front of and behind the eye.

The present results showed that, the non-infectious causes of Ocular cataract represented 66.6%, most of examined samples were collected at summer which may be due to sunburn lesions. The accepted explanation to such phenomena is the exposure to ultraviolet radiation which may destruct skin and eyes of fish kept in shallow water (Walls, 1967, Sleucke et al., 1968- Bullock and Roberts 1981., and Mc Ardle and Bullock, 1987). Exposure of Salmon to temperature below ambient resulted in corneal opacity (reversible), which may occur due to the precipitation of low molecular weight lens proteins at reduced temperature (Loewenstein and Bettelheim, 1979 - and Bruno and Raynard., 1994).

Tilapia species can live in freshwater or brackish water, many investigators suggest that, transferring (migration) fish from fresh to sea water often involves the lens fiber cells. The osmotic loss of internal fluid creates a cloudiness within the lens, such type of cataract is reversible (Brandt. et al., 1986. and Iwata. et al., 1987).

Cataract may result from several non-infectious causes including deficiency of amino acids (methionine and cystine), trace elements (Zinc) and vitamins (riboflavin), such explanation was supported by many authors (Poston et al., 1977-, Ketola, 1979-, Hughes et al., 1981., Hughes, 1985. and Richardson et al., 1986). The non-infectious toxic substance causing Ocular cataract recorded by Khalil, (1998); He found that Bayluscide have a corrosive action on the eye when *Oreochromis niloticus* exposed to 0.1 ppm Bayluscide for 6 weeks, and when histopathological examination carried out no changes have been reported.

On the other hand, the infectious causes of ocular cataract in the present study were *Aspergillus flavus* (5.88%) and *Flexibacter columnaris* (1.96%) with complete loss of the eye as shown in Fig (3) and (4). Many investigators noticed the relationship between *Aspergillus flavus* infection either natural or experimentally and fish eye cataract, as Olufemi and Roberts (1986), who noted that *Tilapia* maintained at 18°C and 26°C and fed daily for one week on pelleted diet contaminated with *A. flavus* accompanied with corneal changes and esophthalmia. Whereas Manal Adel (1988) found that the most clinical signs associated with natural mycotic infection (*A. flavus*) in *Oreochromis niloticus* were exophthalmia and eye cataract. Mechanical abrasion of the eye may play a role as a portal of entry to such opportunistic bacterium and fungi which abled to destroy completely the eye (Ubels and Edelhauser 1982).

Absence of eye flukes in wet preparation of the eye content or in histopathological examination as major causative agents of parasitic eye cataract (Betterton, 1974. and Shariff et al., 1980) indicating that, not only parasitic eye fluke is the causative agent of ocular cataract but also radiation, mechanical abrasions, nutritional deficiency and toxic substances in water could be a possible causes of such affection.

**Pathological findings :**

Microscopically, the cornea showed ulceration and desquamation of the stratified squamous epithelium of the outer layer of the cornea. Meanwhile edema of the corneal stroma was evident where the collagenous connective tissue of the substantia propria was separated by clear spaces represented the sites of edematous fluid (Fig. 5). This could be attributed to that the corneal ulceration results in edema of the dermal half of the stroma (Edelhauser, 1983., Ubeis., 1987., and Ferguson, 1989). In addition to the cornea of freshwater fish develops more severe edema than that of marine species presumably the result of the greater osmotic difference between corneal stroma and the surrounding freshwater environment (Brandt, 1988 and Iwata et al., 1987). The inner part of the corneal stroma, which is continuous with a cartilaginous sclera, showed edema and leukocytic infiltration of mainly round cells (Fig.6). Other cases of eye cataract, from which *Aspergillus flavus* was isolated, showed epithelial hyperplasia and vacuolation of the corneal stratified squamous epithelium of the cornea. Numerous melanomacrophages were noticed infiltrating the corneal stroma (Fig.7). An area of caseous necrosis could be seen under the substantia propria. Epithelial pigmentation of the cornea was represented by the presence of dark eosinophilic pigment within the corneal stratified squamous epithelial layer (Fig.8). Such pigment may be a tapetal pigment migrated from the pigment layer which forms a tapetum lucidum and melanin. The migration of such pigment may be accompanied the movement for adaptation for various light intensities (Walls, 1967 and Bruno and Poppe, 1996). The epithelial hyperplasia and the epithelial pigmentation could be attributed to the chronic irritation changes of *Aspergillus* infection. Other cases of eye cataract, from which *flexibacter* bacteria was isolated, showed vascularization of the corneal stroma. The latter showed numerous nucleated eye thrombocytes, round cells and melanin laden macrophages (Fig. 9 & 10). Corneal vascularization seems to occur only in most chronic and severe cases (Copeland, 1974., Grizzle and Rogers 1976). Meanwhile, the presence of numerous melanin laden macrophages may indicate chronic superficial stromal keratitis (Gorman, 1982).

Table 1 : Showing prevalence of eye cataract among some freshwater fishes.

Fish species	No. examined	No. affected fish	% of affection
<i>O. nilotica</i>	175	19	10.8
<i>Tilapia zillii</i>	180	28	15.5
<i>O. aureus</i>	100	3	3
<i>Clarias lazera</i>	55	1	1.8
Total	510	51	10

Table 2 : Showing causes of eye cataract among the examined freshwater fishes.

Total No.	Asp. Flavus		Flexibacter columnals		Macrophage aggregation + Debris		Non-Infectious Cause		Parasitic Causes	
	No.	%	No.	%	No.	%	No.	%	No.	%
51	3	5.88	1	1.96	13	25.5	34	66.6	0.0	0.0

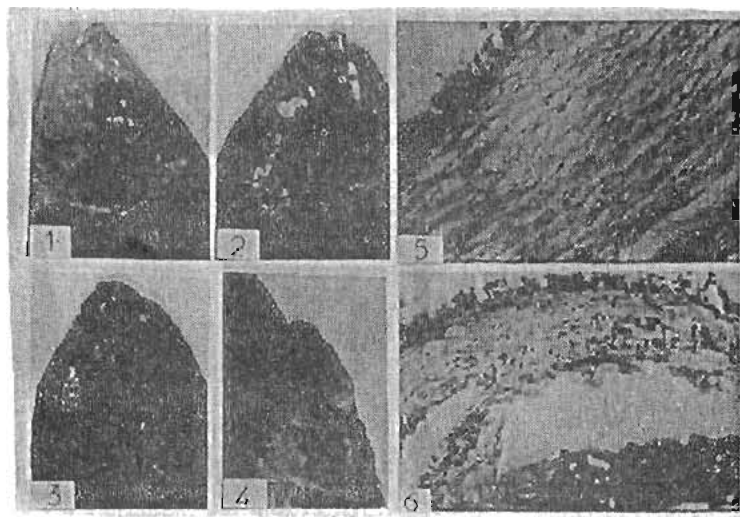


Fig. 1 : Eye cataract showing opacity of the cornea with keratitis in *Oreochromis niloticus*  
 Fig. 2 : Salinity adptallon cataract in *Oreochromis niloticus*.  
 Fig. 3 : Eye cataract with complete loss of the eye.  
 Fig. 4 : Eye cataract with complete less of the eye resulting from flexibacter infection in *Oreochromis niloticus*.  
 Fig. 5 : Cornea of *Oreochromis niloticus* showing edema of substantia propria (H&E x 400).  
 Fig. 6 : Cornea of *Oreochromis niloticus* shoeing edema and lenkocytic infiltration of mainly round cells in the inner part which is continuous with a cartilaginous sclera (H&E x 400).




Fig. 7 : Cornea of *Oreochromis niloticus* showing numerous melanomacrophages infiltrating the corneal stroma (H&E x 400).  
 Fig. (8) : Cornea of *Oreochromis niloticus* showing dark eosinophilic pigment within the corneal stratified squamous epithelial layer (H&E x 1000).  
 Fig. (9) : Cornea of *Oreochromis niloticus*, showing corneal stroma infiltrated with round cells and melanin laden macrophages (H&E x 1000)  
 Fig. (10) : Cornea of *Oreochromis niloticus*, showing vascularization of the corneal stroma with numerous nucleate erythrocytes and melanin laden macrophages (H&E x 1000).

## REFERENCES

- Betterton, C. (1974) : Studies on the host specificity of the eye fluke, *Diplostomum spathaceum*. In brown and rainbow trout, parasitology, 69: 11-29
- Brandt, T. M.; Jones, R. M. and Koke, J. R. (1986) : Corneal cloudiness in transport large-mouth bass. Prog. Fish. Cult. 48, 199-201.
- Bruno, D. W. and Poppe, T. T. (1996) : A colour Atlas of Salmonid diseases. Academic press. 24-28 Oval Road, London, NW1 7DX.
- Bruno, D. W. and Raynard, R. S. (1994) : The effect of water temperature on eye opacity in Atlantic salmon, *Salmo salar*. L. Bull. Eur. Assoc. Fish. Pathol. 14, 86-88.
- Bullock, A. M. and Roberts, R. J. (1981) : Sun burn lesions in salmonid fry: a clinical and histopathological report. J. Fish. Dis. 4, 271-275.
- Edelhauser, H. F. (1983) : Pathogenesis of corneal edema. (Roberts Memorial lecture). Trans 14th.
- Ferguson, H. W. (1989) : System pathology of fish. Iowa State University/Press./Ames.
- Hughes, S. G. (1985) : Nutritional eye diseases in Salmonids: A review. Prog. Fish. Cult. 47, 81-85.
- Hughes, S. G., R s, R. C., Nickum, J. G. and Rumsey, G. L. (1981) : Bio microscopic and histologic. Pathology of the eye in riboflavin deficient rainbow trout (*Salmo gairdneri*). Cornell vet. 71:269-279.
- Iwata, M., Komatsu, S., Colle, N. L., Niskioka, R. S. and Bern, H. A. (1987) : Ocular cataract and seawater adaptation in Salmonids. Aquaculture 66, 315-327.
- Kabunda, M. Y. and Sommerville, C. (1984) : Parasitic worms causing the rejection of tilapia (*Oreochromis species*) in Zaire. British Veterinary Journal. 140: 163-168
- Kent, M. L.; Margolis, L. and Fourine, J. W. (1991) : A new eye disease in peb-reared chinook salmon caused by metacestodes of *Gilquinia squali* (Trypanorhyncha). J. Aquat. Animal Health., 3, 134-140.
- Ketola, H. G. (1979) : Influence of dietary zinc on cataracts in rainbow trout (*Salmo gairdneri*). J. Nutr. 109: 965-969.
- Khalil, R. H. (1998) : Effect of Bayluscide R on some cultured fresh water fish *Oreochromis niloticus*. Ph.D Thesis. Fac. Vet. Med. Alex. University.
- Lillie, R. D. and Fulmen, H. M. (1976) : Histopathological techni and practical histopathology.



The black stone Division, New York. Acad. Sci.

- Loewenstein, M. A. and Bettelheim, F. A. (1979)** : Cold cataract formation in fish lenses. *Exp. Eye. Res.* 28, 651-663.
- Lucky, Z. (1977)** : Methods for diagnosis of fish diseases. Ed. Hoffman, G.L. Amerind Publishing co., Pvt, Ltd. New Delhi, N.Y.
- Manal, Adel. (1988)** : Studies on mycotic infection in fresh water fish. M.V.Sc. Thesis. Zagazig Univ.
- Mc Ardle, J. and Bullock, A. M. (1987)** : Solar ultra violet radiation as a causal factor of ( summer syndrome) in cage-reared Atlantic salmon, *Salmo salar* L.: a clinical and histopathological study. *J. Fish. Dis.* 10, 255-264.
- Odufemi, B. E. and Roberts R. J. (1986)** : Introduction of clinical aspergillomycosis by contaminated diet to tilapia (*Oreochromis niloticus*): *J. Fish. Dis.* 9, 123-128.
- Paperna, I. (1950)** : parasites, infections and diseases of fish in Africa Food and Agriculture Organization, UN. CiFA. Technical paper No.7.
- Poston, H. A.; Reis, R. C.; Rumsey, G. L. and Ketola, H. G. (1977)** : The effect of supplemental dietary amino acids, minerals and vitamins on Salmonids fed cataractogenic diets. *Cornell vet.* 67: 472-509.
- Richardson, N. L.; Higgs, D. A. and Beames, R. M. (1986)** : The susceptibility of juvenile chinook salmon (*Oncorhynchus tshawytscha*) to cataract formation in relation to dietary changes in early life. *Aquaculture.* 52: 237-243.
- Shariff, M.; Richards, R. H. and Sommerville, C. (1980)** : The histopathology of acute and chronic infections of rainbow trout *Salmo gairdneri* Richardson with eye flukes, *Diplostomum* sp. *J. Fish. Dis.* 3, 455.
- Steucke, E. W., Jr.; Allison, L. H.; Piper, R. G.; Robertson, R. and Bowen, J. T. (1968)** : Effects of light and diet on the incidence of cataract in hatchery - reared lake trout. *Prog. Fish. Cult.* 30, 220 - 226.
- Ubels, J. L. and Edelhauser, H. F. (1982)** : Healing of corneal epithelial wounds in marine and fresh water fish. In *current. Eye. Research*, vol. 2, 613-619. Oxford: IRL Press Ltd.
- Walls, G. L. (1967)** : The Vertebrate Eye and Its Adaptive Radiation. New York: Hafner. Publishing. Co. -465.
- Wall, A. D. and Richards, R. H. (1992)** : Occurrence of cataracts in triploid Atlantic salmon (*Salmo salar*) on four farms in Scotland. *Vet. Rec.* 131, 553-557.

## الملخص العربى

## المسببات المحتملة ومعدل إنتشار عتامة العين فى أسماك المياه العذبة

## المشركون فى البحث

د. فيولا حسن زكى د. أحمد فوزى الشايب\*

قسم الأمراض الباطنة والمعدية والأسماك - قسم الباثولوجيا\*

كلية الطب البيطرى - جامعة المنصورة

فى هذه الدراسة تم تجميع عدد ٥١٠ عينة أسماك مياه عذبة من أنواع البلطى والقراميط من أماكن مختلفة فى محافظاتى الدقهلية والبحيرة. تم فحص هذه العينات إكلينيكيًا بالعين المجردة لوجود عتامة بالعين، وكان معدل إنتشار عتامة العين فى البلطى الزيللى والبلطى النيللى والبلطى الأوريا والقراميط ١٥٥٪ - ١٠٠ر٨٪ و ٣٪ و ١٨ر٨٪ على التوالى، ومن نتائج العزل الطفيلى والفطرى والبكتيرى وجد أن مسببات عتامة العين فى الأسماك والتى تسببها فطر الاسبرجلس قلاس نسبتها ٥٨٨٪ وبالنسبة للعزل البكتيرى وجد أن بكتريا الفلكس باكتركولنارس بنسبة ١٩٦٪ بينما بالنسبة للعزل الطفيلى كان سلبي - بالنسبة لمسببات عتامة العين الغير معدية كانت نسبتها ٦٦ر٦٪ أما نسبة ٢٥ر٥٪ فكانت مصاحبة لعتامة العين التى تحتوى فى داخلها على خلايا الماكروقيج وتحلل خلايا العين.

وقد تم تسجيل نتائج الدراسة الهستوباثولوجية لطبقات العين المصابة.