

Prevalence and clinical presentation of skin affections in donkey (*Equus asinus*) in Egypt

Mohamed Sayed-Ahmed¹, Ahmed Ahdy², Emad Younis¹, Sabry El-khodery¹

¹Department of Internal Medicine, Infectious and Fish Diseases, Faculty of Veterinary Medicine, Mansoura University, Mansoura 35516, Egypt.

²National Research Center, El-Dokki, Egypt.



ARTICLE HISTORY

Received: 30.04.2021

Revised: 16.06.2021

Accepted: 19.06.2021

Correspondence to Mohamed Sayed Ahmed; E-mail: drzakaria-infect@hotmail.com

ABSTRACT

Objective: To document prevalence and clinical presentation of skin diseases in donkeys as well as to investigate predilections for the most common conditions.

Design: Epidemiological study

Animals: A total of 1134 donkeys at northern Egypt were investigated.

Procedures: A questionnaire was constructed to verify the number of infected contact animals as well as the associated factors. Physical examination was carried out and the distribution of skin lesions was recorded. Skin scraping and biopsy were obtained to perform bacteriological, mycological and histopathological examinations.

Results: Thirty-five (3.09%) Out of 1134 noticed donkeys had skin affections including mange (18/35; 51.42%), dermatophytosis (6/35; 17.14%), bacterial dermatitis (6/35; 17.14%) urticaria (2/35; 0.57%) and allergic dermatitis (3/35; 0.86%).

Conclusion and clinical relevance: The mange and dermatophytosis are the prevalent skin diseases in donkeys. Contact with other animal species of contaminated environment may contribute to the occurrence of the diseases.

Keywords: Skin affections; prevalence; diagnosis; donkeys; Egypt

1. INTRODUCTION

The donkey or ass (*Equus asinus*) is a species utilized throughout the world primarily as a draft animal and occasionally for other functions such as a meat source or as pets. Although closely related to horses and zebras (with both of which they can produce sterile hybrids), they have some unique features of their own in regards to disease [1]. In Egypt, donkeys are widely spread and economically important animals used for transport, whether riding, pack transport, or pulling carts. They provide more prominent mobility with which to face erratic rainfalls and are of worth in conveying firewood, loads, including water, household structures, goods, and children. However, these animals have not yet been given sufficient care, although they are subject to many diseases, which affect their viability and lower their ability to work [2]. Most descriptions of skin disease in donkeys are reported in small case series, textbooks or review articles [3].

Skin diseases are a source of equine suffering through annoyance, irritability, pruritus, disfigurement, secondary infections, myiasis, and increased susceptibility to other diseases [4]. Skin disease in donkeys is less common than in horses, but is easily overlooked. Little published material exists on this important area of equine medicine [5]. Panel reports of veterinary practitioners in 1981 and 1986 found that dermatophytosis, dermatophilosis, urticaria, Insect hypersensitivity, onchocerciasis, eosinophilic granulomas, papillomas, sarcoids and nutritional seborrheas were the most

commonly encountered equine skin disorders [6-7]. Insect bite hypersensitivity, caused by *Culicoides spp.*, has been reported previously in donkeys. It is interesting to note that pruritus was not a common clinical presentation despite the high prevalence of ectoparasites and insect bite hypersensitivity.

The prevalence of sarcoids in donkeys has been reported to be most common in the fourth year of life and, accounted for an even higher percentage of overall tumors compared with the highest reported percentage of sarcoids in horses [1,8]. The investigation of dermatologic disorders follows the standard approach, but is often influenced in donkeys by a lack of background information. A logical and comprehensive clinical approach is essential under the circumstances so that as much information can be gleaned as possible in respect of both the animal itself or the presenting sign in terms of onset, progression, and prior treatment attempts [9]. To the best of the authors' knowledge, a large case series explaining skin diseases in donkeys has not been published especially in Egyptian donkeys. Thus, the purpose of this retrospective study to document skin diseases and their prevalence and clinical presentation in donkeys and to investigate predilections for the most common conditions.

2. MATERIALS AND METHODS

2.1. Ethical approval

This study was certified, approved and performed according to the ethics of committee of the Faculty of veterinary medicine, Mansoura, University, Mansoura, Egypt.

2.2. Study area

For 1 year, an epidemiologic study was carried out in two governorates of central Egypt (Cairo and Giza). Study area is located in northern Egypt, known as Lower Egypt, 165 kilometers (100 mi) south of the Mediterranean Sea and 120 kilometers (75 mi) west of the Gulf of Suez and Suez Canal. The area is along the Nile River, immediately south of the point where the river leaves its desert-bound valley and branches into the low-lying Nile Delta region.

2.3. Animals

A total of 1134 donkeys, were examined for the presence of skin lesions all over a year. Clinical cases were obtained from two Egyptian governorate lying northeast of Cairo (El-Dakahlia and Al Gharbia) and deworming records of Brooke animal hospital mobile clinics in these areas. A questionnaire was directed to all owners including animal gender, age, and distribution of skin lesion, management system, and number of infected contact animals as well as previous treatment.

2.4. Clinical examination

Competent clinical history and physical and dermatologic examinations for selected donkey were carried out according to standard methods [4]. This study protocol was approved by the Committee of Animal Welfare and Ethics, Faculty of Veterinary Medicine, Mansoura University, Egypt.

2.5. Samples and sample processing

2.5.1. Parasitic isolation

Deep scrapings or smears from cutaneous ulcerative granuloma lesions, especially if the yellowish granules are retrieved, for detection of nematode larvae according to standard methods [4].

2.5.2. Mycotic isolation

Skin scrapings, hair plucking, impression smears, and thick crusts were collected from all selected donkeys. Just before sampling, cleaning of the infected area with alcohol 70% was carried out to remove surface contaminants then allow air drying. Samples were obtained from the edge of lesion which correspond the active zone of lesion. Direct microscopical examination was performed using Chlorazol black stain with dimethyl sulphoxide and potassium hydroxide [10]. The dye allows fungal elements to be identified more readily as they will stain green against a light gray background.

2.5.3. Bacterial dermatitis isolation

Thick crusts were collected in sterile petridish. In addition, impression smears and swabs from exudative lesions according to stander methods [4].

2.5.4. Skin allergy and insect bite hypersensitivity

Whole blood was obtained to determine total and differential leukocytic count according to stander methods

[11]. Blood samples were obtained from diseased and control healthy donkeys.

2.5.5. Skin biopsy for dermatohistopathologic examination

Skin biopsy was collected from all selected donkeys according to stander methods [4,12].

2.6. Sample Examination

2.6.1. Parasitological examination of mange

According to standard method [4], skin scrapings were placed on a clean glass slide, a drop of KOH 10% was added then a clean coverslip was applied and left for 10-15 minutes at room temperature or heated for 5-10 seconds without boiling to allow digestion of keratinacious material. Microscopical examination for the presence of living movable mites. The sample considered positive if one mite was identified [13,14].

2.6.2. Mycological isolation for dermatophytosis

According to standard method [10], skin scrapings, hair plucking, impression smears, and thick crusts were collected from all selected donkeys. Direct microscopical examination was performed using chlorazol black stain with dimethyl sulphoxide and potassium hydroxide. The dye allows fungal elements to be identified more readily as they will stain green against a light gray background.

2.6.3. Fungal identification

According to standard method [15,16,17], skin scraping and hair was cultured onto two types of sabouraud, cycloheximide-chloramphenicol agar media. Plates were incubated at 37°C, with 30% humidity for 30 days and checked daily for fungal growth. Based on the colonial macromorphology, micromorphology, and biochemical tests, the identification of fungi was carried out.

2.6.4. Bacteriological examination

2.6.4.1. Direct microscopy

According to stander methods [18], small pieces were taken from the underside of the crust and soften in few drops of distilled water on a clean glass slide. A smear was made from soften crust, swab and impression smear and stained by geimsa or gram's stain. Then examined under oil immersion lens for the characteristic shape of bacteria and *dermatophilus congolensis*. This was

2.6.4.2. Bacterial isolation

According to stander methods [18], a small amount of scab material was grinded up, placed in a screw capped bottle, moistened with two ml of sterilized distilled water and allowed to stand open for three and half hours on the bench. Then the opened bottle transferred to candle jar with a candle burned within the jar to obtain 20% CO₂ tension (so the motile zoospores will be chemotactically attracted to the CO₂

enhanced atmosphere and move to the surface of distilled water). After 15 minutes, the bottle was carefully removed and samples taken from the water surface with a bacteriological loop and seeded on Brain heart infusion agar (LABM, UK, B.No.102257/058) plates then incubated at 37°C in 10% CO₂ tension for 24 to 48 hours. The suspected colonies were identified on the basis of their macromorphology on the medium and their micromorphology by taking a part of the colonies on clean slide and stained by geimsa or gram's stain.

2.7. Statistical analysis

All data analysis was performed by using statistical software program (SPSS for Windows, Version 15.0, and USA). Association between the occurrence of infection by dermatophytes spp. and the hypothesized risk factors was firstly carried out by univariate analysis using chi square (χ^2 -test). Variables with significant association at P<0.05 (two-sided) were subjected to the multivariate logistic regression model. The results were each expressed as P value and odds ratio (OR) with a 95% confidence interval (CI 95%). Results were considered to be significant at P<0.05.

3. RESULTS

3.1. Prevalence

Thirty-five (3.09%) out of 1134 donkeys had skin lesions as papules, itching, alopecia, crusts, scales and ulcerative granuloma. The prevalence of skin diseases in relation to species, animal's age, seasons and animal's management (Tables 1).

Table 1. Prevalence of skin diseases in 1134 donkeys (*Equus asinus*).

Disease	Prevalence (n=1134)	
	n	%
Dermatophytosis	6	0.53
Bacterial dermatitis	6	0.53
Mange	18	1.59
Cutaneous Habronemiasis	0	0.0
Sweet itch	3	0.26
Tick allergy	0	0.0
Allergic dermatitis	0	0.0
Urticaria	2	0.18
Vitiligo	0	0.0
Equine wart	0	0.0

n: Number of cases

3.2. Clinical and diagnostic findings of mange

In Table 1, eighteen (1.59%) donkeys presented with suspected lesions of mange manifested as an undescribed localized irregular skin lesions, with alopecia, papules, scales and crusts (Figure 1). There was mild to moderate pruritus in all cases. The lesions distributed with highest incidence on legs (20.9%), Back (11.6%), legs (11.6%), Neck (11.6%), Croup (9.3%), hindquarters (7%), Head (7%) and chest (7%) as shown in Table 2.

In Table 3, eight (44.4%) donkeys presented with single and multiple lesions of mange compared to two (11.1%) donkeys with generalized lesions of mange.

Table 2. Distribution of lesions of mange in 43 affected donkeys (*Equus asinus*).

Area	Donkey (n=43)
Head	3 (7%)
Mane	2 (4.7%)
Neck	5 (11.6%)
Chest	3 (7%)
Girth	1 (2.3%)
Shoulder	0 (0%)
Withers	5 (11.6%)
Thorax	2 (4.7%)
Flank	0 (0%)
Abdomen	0 (0%)
Back	5 (11.6%)
Croup	4 (9.3%)
Hindquarter	3 (7%)
Tail	1 (2.3%)
Legs	9 (20.9%)

n = total number of cases have mange lesions on each body area

Table 3. Number of affected areas in mange.

Affected areas	Donkey (n=18)
Animal with single affected area	8 (44.4%)
Animal with multiple affected area	8 (44.4%)
Animal with generalized lesion	(11.1%)

n= number of infested donkeys with mange

Table 4. Distribution of dermatophytosis lesions on donkey body

Area	Donkey (n =19)
Head	4 (21.1%)
Neck	2 (10.5%)
Chest	3 (15.8)
Girth	0 (0%)
Thorax and barrel	3 (15.8%)
Abdomen	1 (5.3%)
Back, loin and Croup	2 (10.5%)
Hindquarters	3 (15.8%)
Legs	1 (5.3%)

3.3. Clinical and diagnostic findings of dermatophytosis

Six (0.53%) out of 1134 noticed donkeys were suffered from dermatophytosis. The most clinical signs were characterized by multiple tufted to crusted papules in the beginning of the disease, when hairs plucked up from these lesions lead to irritability of the donkey due to variable degrees of pain are often present in early lesions. After that, the lesions of alopecia became annular or oval about 5 to 20 cm in diameter with thin or thick crusts. Hairs can easily be

plucked from lesions leaving a glistening bare skin. Alopecia and a prominent silvery scaling are seen in older lesions. Lesions typically expanded peripherally and coalesced to form polycyclic shapes. Pruritus was not seen in any case except in mixed infection with mange or with allergic dermatitis and sweet itch. Distribution of lesions on the body and the number of affected areas (Table 4). In Table 5, the microsporin spp., consider the most prevalent dermatophytes isolated from donkey especially *microsporum canis* and *microsporum gypseum*.

Direct microscopical examination of infected hairs appeared swollen and frayed, irregular or fuzzy in outline. The clear definition between cuticle, cortex, and medulla was lost. Ectothrix invasion of hair with arthrospores appeared in a mosaic pattern on the surface of the hair or in chains of arthrospores on the hair. Hyphae may be seen within hair shaft and grow outward (Figure 2 and 3).

Table 5. Number of dermatophytes isolates from donkey.

Affected area	Donkey (n =5)
Trichophyton spp	0
<i>T. equinum</i>	0
<i>T. mentagrophytes</i>	0
<i>T. tonsurans</i>	0
Microsporum spp	5
<i>M. canis</i>	3
<i>M. gypseum</i>	2
<i>M. audouinii</i>	0

n: Number of cases

Table 6. Number of affected area with dermatophytosis.

Affected area	Donkey (n=6)
Single area	0 (0%)
Multiple areas	5 (83.3%)
Generalized area	1 (16.7%)

n= number of infected equine with dermatophytosis

Histopathological findings showed numerous arthroconidia and hyphae in the hair follicle and shaft by PAS And by special stain (GMS) (Figure 4). There is one donkey suspected of dermatophilosis due to characteristic clinical lesions of extensive crusting and matted hair. The direct microscopical examination revealed fine, branching, and multiseptate hyphae, which divide transversely and longitudinally to form cuboidal packets of coccoid cells arranged in two to eight parallel rows within branching filaments (railroad track appearance) which is characteristic to dermatophilus congolensis and neutrophils were the predominant inflammatory cell (Figure 5).

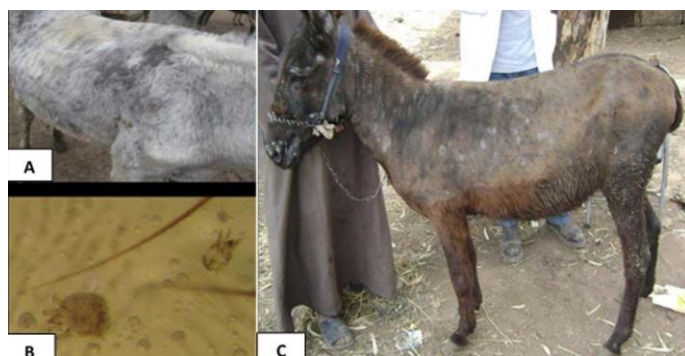

Figure 1. Mange lesions on the shoulder and neck of donkey. (A) *Psoroptes equi* female adult and larvae in skin scraping (B). Donkey with circumscribed areas of alopecia with scales due to *M.gypseum* (C).

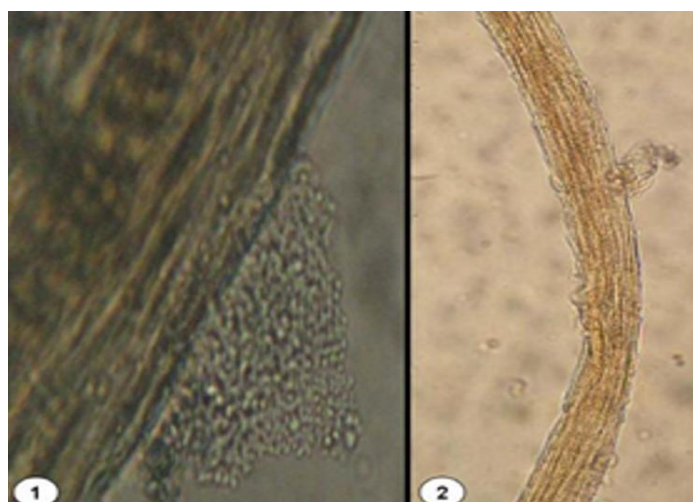


Figure 2. Direct microscopical examination by KOH 20 % (400X); 1. Arthrospores arranged in mosaic form (ectothrix) on hair shaft; 2. Infected hair showing ectothrix and endothrix arthrospores.

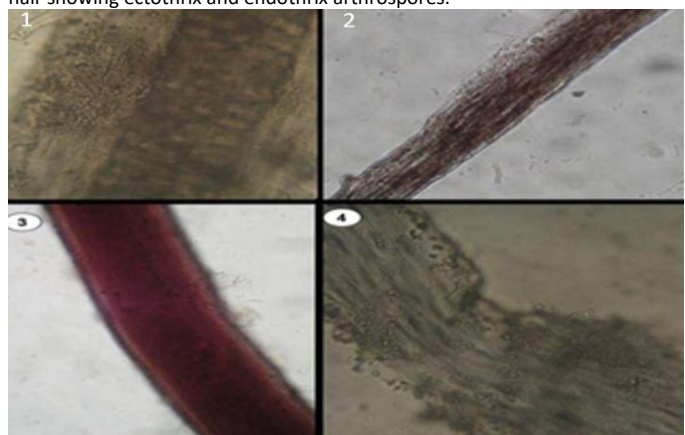


Figure 3. Direct microscopical examination by Chlorazol black-DMSO-KOH (400X); 1. Arthrospores in the hair cortex (ectothrix); 2. Infected hair showing ectothrix and endothrix arthrospores; 3. Hyphae and arthrospores on hair shaft; 4. Hair follicle shaft junction showing arthrospores.

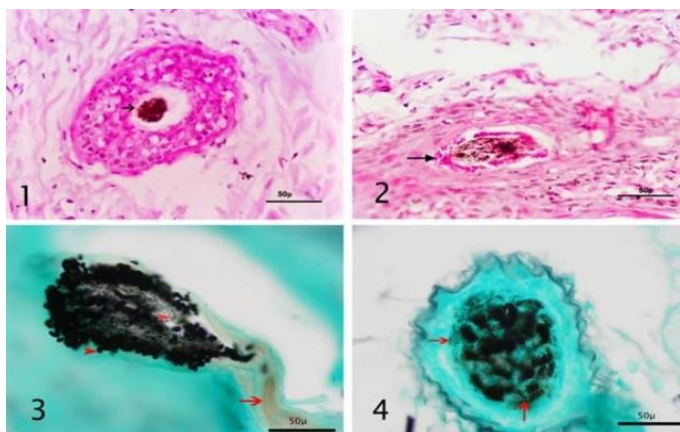


Figure 4. Histopathological examination of dermatophytosis skin biopsy; 1. Dermis showing arthrospores surrounding hair shaft (arrow) "PAS stain"; 2. Arthrospores stained red (arrow) surrounding and invading damaged hair shaft "PAS stain"; 3. Longitudinal section of hair follicle showing arthrospores and hyphae replacing the hair bulb (red arrow head) with intact hair shaft (red arrow)"GMS stain"; 4. Cross section of hair follicle stained with GMS showing black arthrospores"red arrow".

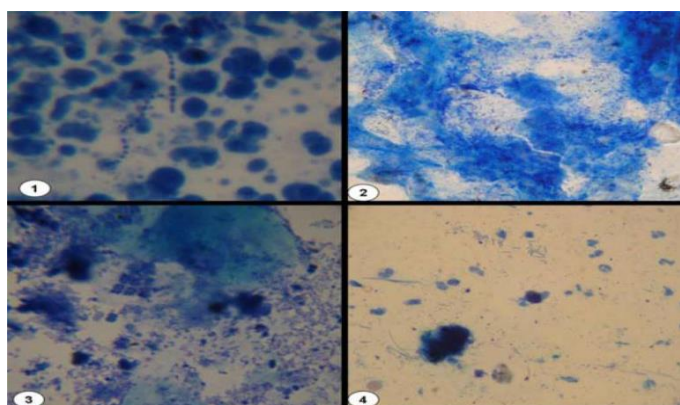


Figure 5. Direct microscopical examination 1000X (Geimsa staining); 1. Cocci arranged in chains with neutrophils; 2. Cocci in clusters and chains with neutrophils; 3. Parallel rows of cocci"railroad tracks"(dermatophilosis); 4. Branched filaments (dermatophilosis).

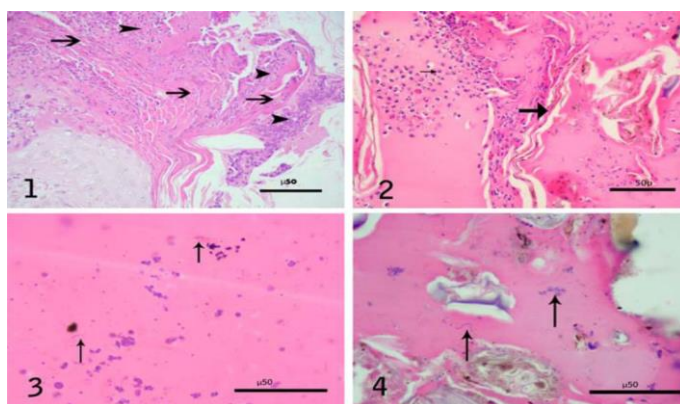


Figure 6. Histopathology of bacterial dermatitis lesions (H & E). 1. Thick, palisading crust showing alternated layers of purulent exudate (arrow head) and keratinized layer (arrow); 2. Crust showing alternated layers of purulent exudate (thin arrow) and keratinized layer (thick arrow); 3. High magnification to show bacterial filaments and cocci (arrow) in the crust; 4. Crust showing bacterial filaments and cocci (Arrow).

3.4. Clinical and diagnostic finding of bacterial dermatitis

Clinical examination revealed that six (0.53%) out of 1134 donkeys with suspected lesions of bacterial dermatitis which were seen in form of papules, pustules, acne, exudative dermatitis and suppuration or in form of crusty lesions with matted hair. Most cases were presented in summer season. Lesions occurred everywhere on the body but commonly on the pastern region, the croup area and under saddle and harness area. Histopathological examination of thick, palisading crust showing alternated layers of purulent exudate and keratinized layer and neutrophils with gram-positive cocci in clusters or chains (Figure 6).

4. DISCUSSION

Little information is available on the prevalence of diseases of donkeys in Egypt. The present study provided an overview on the prevalence of skin affections in donkeys, clinical findings and treatment outcomes. The present study was carried out on 1134 donkeys of different species, breeds, ages, sexes and localities during the period from March 2009 to February 2010. Study the prevalence of skin disease in donkeys at some localities in Egypt revealed 35(3.09%) donkeys were suffered from skin diseases. Mange was diagnosed in six donkeys, which was one of the most common skin disease as it represented in (1.59%) of the skin diseases affecting donkeys, followed by dermatophytoses and bacterial dermatitis (0.53%). Our results are in agreement with that of previous reports in equines [4,10,19]. The Top ten equine dermatoses seen were dermatophytosis, insect hypersensitivity (sweet itch), psoroptic mange, bacterial dermatitis, cutaneous habronemiasis, allergic dermatitis, urticaria, tick dermatoses, equine wart and vitiligo, the similar result was reported by [4,20,21], who found the similar results.

Mange was diagnosed in 18 donkeys representing 1.59% of the skin diseases in donkeys. The clinical findings were undescribed localized irregular skin lesions, with alopecia, papules, scales and crusts. The lesions distributed with highest incidence on legs (20.9%), Back (11.6%), legs (11.6%), Neck (11.6%), Croup (9.3%), hindquarters (7%), Head (7%) and chest (7%). This distribution are in agreement with that of previous reports in donkeys the similar clinical findings and distribution of lesions were observed by previous results [4,22,23].

Circumscribed skin lesions of dermatophytosis were distributed on several parts of the body with highest incidence on Head (21.1%), chest, thorax and hind quarters (15.8%), neck, back, lion, and croup (10.5%), and This distribution are in agreement with that of previous reports in equine [4,21], Lesions were commonly found on areas in contact with harness as neck, chest, back, hindquarter and head in donkeys as reported previously [24], who found the main lesions of dermatophytosis were under the harness in draft horses and donkeys. The infectivity of contaminated harness may remain

for long periods, which play a major role as source of infection to donkeys [25], while the head, neck and chest lesions were more common in equines, which reared congregated together into a stable yard.

Generalized skin lesions all over the body shown in 1 (16.7%) donkeys, while generalized which was observed mostly in younger ages and this agrees with previous reports [4,12], who reported generalized dermatophytosis, which is uncommon in immunosuppressed horses and donkeys. The most clinical signs of dermatophytosis were multiple tufted to crusted papules with variable degrees of pain are presented in 5 (83.3%) donkeys. Annular or oval areas of alopecia with crusts that may be thin or thick with hairs can easily be plucked from lesions leaving a glistening bare skin. Lesions typically expand peripherally and may coalesce to form polycyclic shapes. Alopecia and a prominent silvery scaling were seen in older lesions. This result coincides with earlier findings [4,19,27]. The donkey's skin samples examination revealed *Microsporum canis* and *Microsporum gypsum* isolation and this nearly agrees with the previous results [28]. These results may be attributed to the nature of donkey's management and work, which usually in contact with other animal species in study area.

Bacterial dermatitis was diagnosed in six donkeys, which represented 0.53% of skin diseases. The diagnosis depended on the clinical signs, which characterized by exudative dermatitis, pustules, crust formation, and depended on the cytological examination of impression smears or swab or direct smear of crust and skin biopsy that revealed bacterial colonies. The bacterial isolation was failed due to highly contamination of skin lesions [4]. The lesions occurred everywhere on the body but commonly were found on pastern region, croup and under saddle and harness region. Most clinical cases occurred in summer and spring season coinciding with high work schedules, higher environmental temperature and humidity, increased insect population and poor grooming [4].

Conclusion

Skin affection is a serious problem in donkeys at some localities in Egypt and veterinarians fail in clinical diagnosis and treatment. Mange and dermatophytosis are the prevalent skin diseases in donkeys. Contact with other animal species of contaminated environment may contribute to the occurrence of the diseases. *Microsporum spp* with especial reference to *M.canis* and *M. gypsum* were the common cause of dermatophytosis in Egyptian donkeys.

Conflict of interest

The authors declared that they have no conflict of interest related to this research.

Authors Contributions

This work was carried out in collaboration between all authors. SE, EY designed the study, and interpreted the data. AA and MSA was involved in collection of data and contributed in manuscript preparation. MSA and SE took part in preparing and critical checking of this manuscript. MSA writing-review and editing the manuscript. All authors have read and agreed to the published version of the manuscript.

5. REFERENCES

- [1] Burden F, Thiemann A. Donkeys are different. J Equine Vet Sci 2015; 35: 376-382. <https://doi.org/10.1016/j.jevs.2015.03.005>
- [2] White SD, Bourdeau PJ, Brément T, Vandenabeele SI, Haspelslagh M, Bruet V. and van Oldruitenborgh-Oosterbaan MMS Skin disease in donkeys (*Equus asinus*): a retrospective study from four veterinary schools. Vet Dermatol 2019; 30 (3): 247-e76. <https://doi.org/10.1111/vde.12733>
- [3] Radwan AM., Ahmed NE, Elakabawy LM, Ramadan MY, Elmadawy RS. Prevalence and pathogenesis of some filarial nematodes infecting donkeys in Egypt. Vet World 2016; 9(8): 888-892. <https://doi.org/10.14202/vetworld.2016.888-892>
- [4] Scott DW, Miller WH. Equine Dermatology, 2nd edition, New York, USA, Elsevier Health Sciences 2010. <https://www.elsevier.com/books/equine-dermatology/scott/978-1-4377-0920-9>
- [5] Knottenbelt DC Skin Disorders of the Donkey and Mule. Vet Clin North Am Equine Pract 2019; 35(3): 493-514. <https://doi.org/10.1016/j.cveq.2019.08.006>
- [6] Panel Report Dermatologic problems in horses. Mod Vet Pract 1981; 62:75. <https://www.passeidireto.com/arquivo/47957309/equine-dermatology-second-edition/2>
- [7] Wobeser BK Skin diseases in horses. Vet Clin North Am Equine Pract 2015; (2): 359-76. <https://doi.org/10.1016/j.cveq.2015.04.007>
- [8] Davis CR, Valentine BA, Gordon E, McDonough SP, Schaffer PA, Allen AL, Pesavento P. Neoplasia in 125 donkeys (*Equus asinus*): literature review and a survey of five veterinary schools in the United States and Canada. J Vet Diagn Invest 2016; 28(6): 662-670. <https://doi.org/10.1177/1040638716665659>
- [9] Knottenbelt DC. The approach to the equine dermatology case in practice. Vet. Clin. North Am Equine Pract 2012; 28(1):131-53. <https://doi.org/10.1016/j.cveq.2012.01.004>
- [10] Knottenbelt DC. Formulary of equine medicine. 3rd edition, London, Liverpool University press 1992. <https://bonycuwivy.multinivel.top/formulary-of-equine-medicine-book-19110iz.php>
- [11] Marsella R (2019). Manual of Equine Dermatology. CABI, University of Florida, USA. <https://www.cabi.org/bookshop/book/9781786395085/>
- [12] Wall R and Shearer D (1997) Veterinary Entomology, 1st ed, Chapman and Hall, London, UK. <https://www.springer.com/gp/book/9780412615108>
- [13] Radwan YA, Abdou OMA, Abdel Hamid S, Arab RM. Efficacy and safety of ivomec against camel mange. Vet Med J 1987; 35: 83-84.
- [14] Evans AG, Stannard AA Pruritis: differential diagnosis and treatment. Comp Cont Edu 1986; 8: 652. <http://www.sciquest.org.nz/node/31691>
- [15] Rosychuk R, Yu A. Equine dermatology, an issue of veterinary clinics: equine practice. New York, USA: Elsevier Health Sciences 2013. <https://www.elsevier.com/books/equine-dermatology-an-issue-of-veterinary-clinics-equine-practice/rosychuk/978-0-323-26134-0>
- [16] Ahdy M.M., Sayed-Ahmed M.Z., Younis E.E., Baraka H., El-khodery S.A. Prevalence and Potential Risk Factors of Dermatophytosis in Arabian Horses in Egypt. J Equine Vet Sci 2016; 37: 71-76. <https://doi.org/10.1016/j.jevs.2015.12.008>.
- [17] Quinn PJ, Markey BK, Leonard FC, Hartigan P, Fanning S, Fitzpatrick ES. Veterinary Microbiology and Microbial Disease, 2nd Edition, Wiley Blackwell, Ltd., Oxford ; 2011. <https://www.ncbi.nlm.nih.gov/pmc/articles/PMC340368/>
- [18] Pilsworth RC, Knottenbelt D. Dermatophytosis (ringworm). Equine Vet Edu 2007; 19(3): 151-154.

- <https://beva.onlinelibrary.wiley.com/doi/abs/10.2746/095777307X186929>
- [19] Chermette R., Ferreiro L., Guillot J. Dermatophytoses in Animals. *Mycopathologia* 2008; 166:385-405. <https://doi.org/10.1007/s11046-008-9102-7>
- [20] Awad WSA. Some studies on some infectious skin diseases in animals. M.V.Sc Thesis (Infectious diseases) Cairo University, 1995.
- [21] Osman SA, Hanafy A, Amer SE. Clinical and therapeutic studies on mange in horses. *Vet Parasitol* 2006; 141: 191-195. <https://doi.org/10.1016/j.vetpar.2006.04.039>
- [22] Ural K, Ulutas B, Kar S. Eprinomectin treatment of psoroptic mange in hunter/jumper and dressage horses: A prospective, randomized, double-blinded, placebo-controlled clinical trial. *Vet Parasitol* 2008; 156: 353-357. <https://doi.org/10.1016/j.vetpar.2008.06.018>
- [23] Takatori K, Ichijo S, Tatsuo K, Tanaka I. Occurrence of equine dermatophytosis in Hokkaido. *Jpn J Vet Sci* 1981; 43: 307-313. <https://doi.org/10.1292/jvms1939.43.307>
- [24] Radostits O, Gay C, Hinchcliff K, Constable P. *Veterinary medicine: a textbook of the diseases of cattle, sheep, pigs, goats, and horses*. 10th Edition, Oxford, UK: Elsevier Saunders; 2007 <https://www.elsevier.com/books/veterinary-medicine/radostits/978-0-7020-2777-2>
- [25] Pisseri F, Bertoli A, Nardoni S, Pinto N, Pistelli L, Guidi G, Mancianti F. Antifungal activity of tea tree oil from *Melaleuca alternifolia* against *Trichophyton equinum*: An in vivo assay. *J Phymed* 2009; 16: 1056-1058. <https://doi.org/10.1016/j.phymed.2009.03.013>
- [26] Pereira DIB, de Oliveira LSS, Bueno A, Cavalheiro AS, Schwendler SE, de Azevedo MI, Júnior JCE, Aguiar LC, Santurio DF, Santurio JM, Alves SH. Outbreak of *Trichophyton equinum* var. *equinum* in horses in the south of Brazil. *Ciência Rural* 2006; 36(6): 1849-1853. <http://dx.doi.org/10.1590/S0103-84782006000600028>
- [27] El-Kot, AM. Some studies on skin affections in equines with special reference to similar group in zoo. PhD Thesis Zagazig, University; 1996.